Unconventional Implant Placement Through Impacted Maxillary Canine – A Case Report

dr Ivona Bjenjaš, Dental office BGD Osmeh, Belgrade, Serbia

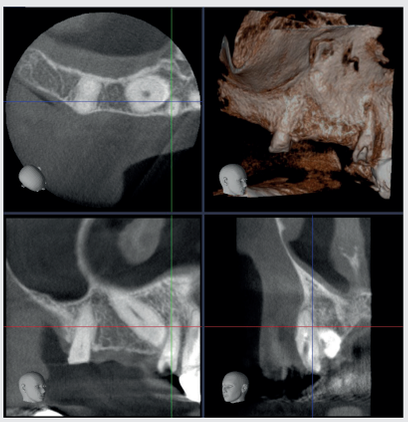

Figure 1 – CBCT small FOV teeth 15-11

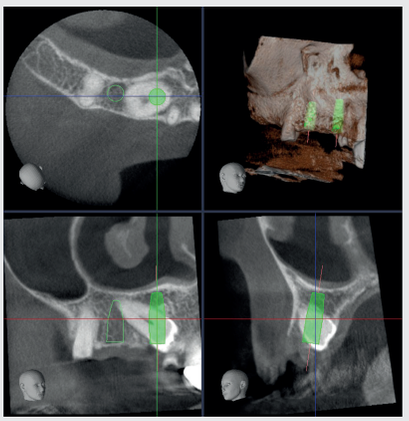

Figure 2 – Implant planning on CBCT

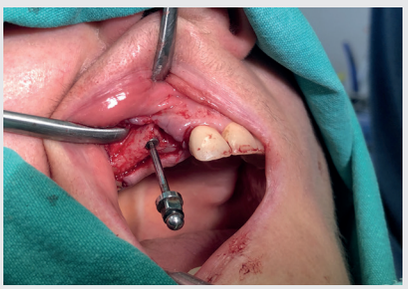

Figure 3 - Implantation

Figure 7 – Healing caps

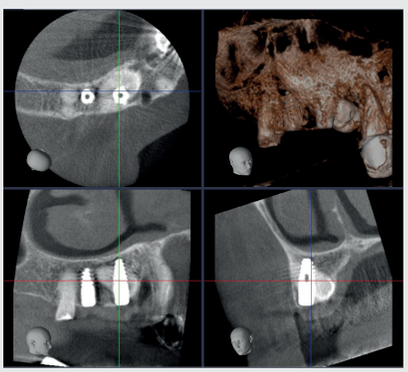

Figure 4 – Control CBCT small FOV

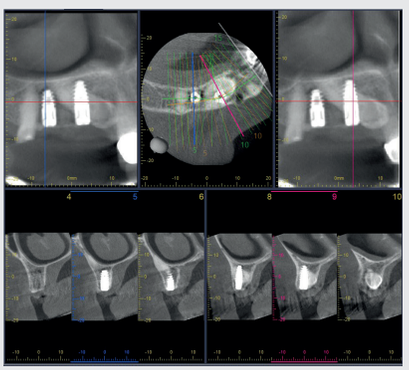

Figure 5 – Control CBCT small FOV

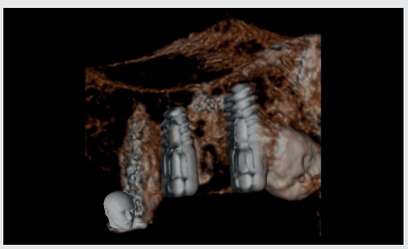

Figure 6 – CBCT small FOV slice along Y plane

Abstract

We described a case report of a 66 years old patient with asymptomatic impacted maxillary canine free of any surrounding pathology.
Extraction of the impacted tooth was avoided because of expected massive bone loss and possible complications.
Two C-Tech implants were placed through the impacted tooth in region 13 and 14.
Primary stability was achieved on 60N/cm.
No postoperative pain, swelling or bleeding was reported by the patient.
After four months implants were uncovered and rehabilitated prosthetically with E-max CAD bridge.

Introduction

Background. Female patient 66 years old needed dental therapy of the upper right partial edentulism of maxilla. Old PMF fixed partial denture was loosened and the extraction of the tooth 12 was indicated. Tooth 15 was indicated for the root treatment and post. Region 14 and 13 were indicated for implant therapy.

Materials & Methods

Dental status was taken. To reduce the patient x-ray exposure following ALARA recommendation only small FOV on CBCT was done. The impacted right upper canine was discovered. Patient knew about it, but it was completely asymptomatic for years and no other surrounding pathology couldn't be seen on CBCT (Figure 1). Extraction of the impacted tooth was avoided because of expected massive bone loss and possible complications (Figure 2). The tooth 12 was extracted. There was no buccal plate after extraction, so this site was excluded for immediate implant placement. Two C-Tech implants were placed through the impacted tooth in region 13 (EL 3,5x11) and 14 (EL 3,5x9) (Figure 3). Primary stability was achieved on 60N/cm. The wound was sutured with 4,0 Nylon.
Control CBCT was taken, expected positions of implants were achieved (Figures 4, 5, 6). Patient was prescribed with antibiotic therapy Sinacillin 0.5g 3x1 for seven days and Ibuprofen 0.4g if needed.

Figure 8 – Definitive restauration

Results

No postoperative pain, swelling or bleeding was reported by the patient. After seven days sutures were removed, the wound healing was uneventful. Tooth 15 was treated and CoCrMo post was made.
After four months implants were uncovered without any difficulties and healing caps were placed (Figure 7). Patient was prosthetically rehabilitated with E-max Cad bridge (Figure 8)

Conclusion

There are only a few case reports done with placing implants into impacted teeth. From our experience protocol deviation is justified in situations when expected bone loss is compromising implant therapy afterward. There should be more studies confirming the safety of such procedures.

References

1. Jarjoura K, Crespo P, Fine JB. Maxillary canine impactions: Orthodontic and surgical management. Compend Contin Educ Dent 2002;23:23–26.
2. Chu FCS, Li TKL, Lui VKB, Newsome PRH, Chow RLK, Cheung LK. Prevalence of impacted teeth and associated pathologies—A radiographic study of the Hong Kong Chinese population. Hong Kong Med J 2003;9:158–163.
3. Cooke J, Wang HL. Canine impactions: Incidence and management. Int J Periodontics Restorative Dent 2006;26: 483–491.
4. Zahrani AA. Impacted cuspids in a Saudi population: Prevalence, etiology and complications. Egypt Dent J 1993;39:367–374.
5. Yavuz MS, Aras MH, Büyükkurt MC, Tozuglu S. Impacted mandibular canines. J Contemp Dent Pract 2007;8:78–85